

PEDIATRICS®

OFFICIAL JOURNAL OF THE AMERICAN ACADEMY OF PEDIATRICS

Propranolol for Severe Infantile Hemangiomas: Follow-Up Report

Véronique Sans, Eric Dumas de la Roque, Jérôme Berge, Nicolas Grenier, Franck Boralevi, Juliette Mazereeuw-Hautier, Dan Lipsker, Elisabeth Dupuis, Khaled

Ezzedine, Pierre Vergnes, Alain Taïeb and Christine Léauté-Labrèze

Pediatrics 2009;124:e423-e431; originally published online Aug 10, 2009;

DOI: 10.1542/peds.2008-3458

The online version of this article, along with updated information and services, is located on the World Wide Web at:

<http://www.pediatrics.org/cgi/content/full/124/3/e423>

PEDIATRICS is the official journal of the American Academy of Pediatrics. A monthly publication, it has been published continuously since 1948. PEDIATRICS is owned, published, and trademarked by the American Academy of Pediatrics, 141 Northwest Point Boulevard, Elk Grove Village, Illinois, 60007. Copyright © 2009 by the American Academy of Pediatrics. All rights reserved. Print ISSN: 0031-4005. Online ISSN: 1098-4275.

American Academy of Pediatrics

DEDICATED TO THE HEALTH OF ALL CHILDREN™



Propranolol for Severe Infantile Hemangiomas: Follow-Up Report

CONTRIBUTORS: Véronique Sans, MD,^a Eric Dumas de la Roque, MD,^b Jérôme Berge, MD,^c Nicolas Grenier, MD,^d Franck Boralevi, MD,^a Juliette Mazereeuw-Hautier, MD,^e Dan Lipsker, MD,^f Elisabeth Dupuis, MD,^g Khaled Ezzedine, MD,^h Pierre Vergnes, MD,ⁱ Alain Taieb, MD,^a and Christine Léauté-Labrèze, MD^a

^aNational Reference Center for Rare Skin Diseases and Departments of ^bNeonatology and ^cSurgery, Children's Hospital, Bordeaux, France; Departments of ^dNeuroradiology and ^eRadiology, Pellegrin Hospital, Bordeaux, France; ^fDepartment of Dermatology, Purpan Hospital, Toulouse, France; ^gDepartment of Dermatology, Strasbourg Hospital, Strasbourg, France; ^hDepartment of Dermatology, Fort de France Hospital, Fort de France, France; ⁱNational Reference Center for Rare Skin Diseases, Saint-André Hospital, Bordeaux, France

KEY WORDS

angiogenesis, β_2 -adrenergic receptors, vincristine, corticosteroids, interferon

ABBREVIATIONS

IH—infantile hemangioma
VEGF—vascular endothelial growth factor
bFGF—basic fibroblast growth factor

www.pediatrics.org/cgi/doi/10.1542/peds.2008-3458

doi:10.1542/peds.2008-3458

Accepted for publication Apr 10, 2009

Address correspondence to Alain Taieb, MD, National Reference Center for Rare Skin Diseases, Children's Hospital, Place Amélie Raba-Léon, F-33076 Bordeaux, France. E-mail: alain.taieb@chu-bordeaux.fr

PEDIATRICS (ISSN Numbers: Print, 0031-4005; Online, 1098-4275).

Copyright © 2009 by the American Academy of Pediatrics

FINANCIAL DISCLOSURE: The authors have indicated they have no financial relationships relevant to this article to disclose.



WHAT'S KNOWN ON THIS SUBJECT: Corticosteroids are currently the mainstay treatment for complicated IHs, with interferon or vincristine as second- or third-line treatment. Because of the partial efficacy and side effects of these drugs, new treatments are needed.



WHAT THIS STUDY ADDS: In this case series, propranolol had consistent, rapid, therapeutic effects. If these findings are confirmed in larger comparative studies, then propranolol could become the first-line treatment for IHs.

abstract

OBJECTIVE: Infantile hemangiomas (IHs) are the most-common soft-tissue tumors of infancy. We report the use of propranolol to control the growth phase of IHs.

METHODS: Propranolol was given to 32 children (21 girls; mean age at onset of treatment: 4.2 months) after clinical and ultrasound evaluations. After electrocardiographic and echocardiographic evaluations, propranolol was administered with a starting dose of 2 to 3 mg/kg per day, given in 2 or 3 divided doses. Blood pressure and heart rate were monitored during the first 6 hours of treatment. In the absence of side effects, treatment was continued at home and the child was reevaluated after 10 days of treatment and then every month. Ultrasound measurements were performed after 60 days of treatment.

RESULTS: Immediate effects on color and growth were noted in all cases and were especially dramatic in cases of dyspnea, hemodynamic compromise, or palpebral occlusion. In ulcerated IHs, complete healing occurred in <2 months. Objective clinical and ultrasound evidence of longer-term regression was seen in 2 months. Systemic corticosteroid treatment could be stopped within a few weeks. Treatment was administered for a mean total duration of 6.1 months. Relapses were mild and responded to retreatment. Side effects were limited and mild. One patient discontinued treatment because of wheezing.

CONCLUSION: Propranolol administered orally at 2 to 3 mg/kg per day has a consistent, rapid, therapeutic effect, leading to considerable shortening of the natural course of IHs, with good clinical tolerance. *Pediatrics* 2009;124:e423–e431

Infantile hemangiomas (IHs) are the most-common soft-tissue tumors of infancy, occurring in 4% to 10% of children <1 year of age, with a clear female predominance (female/male ratio: 2.5–4:1).¹ At birth, IHs may not be apparent or may appear as flat circumscribed lesions with telangiectatic vessels on the surface. Within the first weeks of life, IHs enter a phase of rapid growth with superficial and/or deep components, which lasts usually 3 to 6 months and sometimes up to 24 months.² A period of stabilization for a few months follows, and spontaneous involution usually occurs in several years. Regression is complete for 60% of 4-year-old patients and 76% of 7-year-old patients.³ Most of the time, sequelae are minimal, with residual cutaneous redundancy, fibrous and fatty residues, and telangiectases, which can be treated with late surgery or pulsed-dye laser therapy. Because of this benign, self-limited course, therapeutic abstention is the rule.

However, 10% of IHs require treatment during the proliferative phase,⁴ because of life-threatening locations, local complications, or cosmetic/functional risks.¹ IHs can be life-threatening when present in upper airways and liver, inducing acute respiratory failure and congestive heart failure, respectively. Local complications such as hemorrhage, ulceration, and necrosis can be very painful and may lead to scars that are difficult to repair. IHs in some locations can impair sensory functions; for example, IHs of the upper eyelid can induce anisometropia, astigmatism, and amblyopia. IHs in other locations, such as the lip, nasal tip, or ear, may lead to permanent deformities. In addition, IHs cause at least transient cosmetic disfigurement, which may trigger psychological morbidity first in parents and later in affected children.^{1,5} The conventional approach in complicated cases is to use systemic

corticosteroid therapy as first-line treatment and then interferon or vincristine as second- or third-line therapeutic agents. Even with high dosages (2–5 mg/kg per day), rates of responses to systemic corticosteroid therapy (stabilization or incomplete regression, in most cases) range from 30% to 60%,^{1,6,7} with the effects appearing within the first 2 or 3 weeks of treatment. Moreover, side effects are multiple; most are transient and limited, such as cushingoid facies, insomnia, irritability, stunted growth, and gastrointestinal symptoms, but some may become much more serious, such as hypertension and hypertrophic obstructive cardiomyopathy. Intralesional corticosteroids used for treating palpebral hemangioma can lead to central artery occlusion.⁸ Forty percent to 50% of complicated cases demonstrated complete responses to 1×10^6 to 3×10^6 U/m² per day interferon α (either 2a or 2b), with the first signs of regression appearing after 2 to 12 weeks of treatment.^{1,8,9} Frequent side effects include fever and muscular pains at the beginning of treatment. Hematologic and hepatic toxicity, hypothyroidism, and depression also may occur. Neurotoxicity with spastic diplegia and development delay may occur in up to 10% to 30% of cases. Another treatment option developed more recently is vincristine.^{1,10} Efficacy is close to 100% with 0.05 mg/kg or 1 mg/m² infusions once per week, with IH involution beginning after 3 weeks of treatment. Significant side effects include constipation, transient jaw pains, peripheral neuropathy, hematologic toxicity, and inappropriate secretion of antidiuretic hormone.

We observed serendipitously that propranolol, a well-tolerated, nonselective, β -adrenergic receptor blocker commonly used for cardiologic indications in young children,^{11–13} can control the growth of IHs efficiently. The index

case and the following 10 cases were described briefly in a letter.¹⁴ We now report in detail the observations for those patients and another 21 patients (total $N = 32$) who were treated with propranolol.

METHODS

After dramatic effects were noted in the index case,¹⁴ we obtained the endorsement of the regional ethics committee for a pilot trial in severe cases of IH. In all cases, informed consent was obtained from both parents. This was an observational study. We included all patients with complicated IHs in need of treatment, according to the ad hoc American Academy of Dermatology Guidelines/Outcomes Committee.¹⁵ We excluded infants with cardiovascular disorders contraindicating propranolol use, after a pediatric cardiologist evaluation (see below) or a recent outbreak of wheezing.

Propranolol was given to a total of 32 patients according to the following protocol. At inclusion, a clinical evaluation with photographs and, when possible, an ultrasound examination (measuring the maximal thickness of the lesion and the resistivity index) were performed, together with electrocardiographic and echocardiographic evaluations to rule out treatment contraindications. Treatment was initiated during a short hospitalization of 24 hours or during a day hospital session. Propranolol was prepared by the hospital pharmacy as capsules containing a homogeneous mixture of propranolol and mannitol. The drug was then given at a starting dose of 2 mg/kg per day, in 2 or 3 divided doses. For our first patients, propranolol was administered in 3 divided doses when the IH was particularly alarming, because of the concern about the short half-life of the drug (3 hours). In 4 cases, the initial dosage was 3 mg/kg per day to maximize effi-

TABLE 1 Clinical Characteristics of the 32 Patients

Patient No.	Gender	Location of IH	Indication for Treatment	Previous Treatment With Corticosteroids	Age at Initiation of Propranolol Treatment, mo	Propranolol Dosage, mg/kg per d	Age at End of Corticosteroid Treatment, mo	Rebound After Corticosteroid Treatment	Age at End of Propranolol Treatment, mo	Relapse After Propranolol Treatment	Duration of Propranolol Treatment, mo
1	Male	Nose	Life-threatening (dyspnea) and local complication (columella necrosis)	Prednisone, 3 mg/kg per d; stabilization of IH but hypertrophic myocardiodiopathy	4	3	5.5	No	14	No	10
2	Male	Face (periorbital and parotid areas), axillary fold, and arm	Life-threatening (increased cardiac output) and functional risk (palpebral occlusion)	Prednisone, 3 mg/kg per d then 5 mg/kg per d; inefficient for IH growth and increased cardiac output	2	2	4	No	9	Mild recoloration	7
3	Female	Face (periorbital and parotid areas and lip)	Functional risk (palpebral occlusion)	Prednisone, 2 mg/kg per d; moderately efficient	2	2	4	No	12	Mild recoloration and regrowth when stopped at 9 mo	10
4	Female	Face (periorbital and parotid areas and subglottic location)	Life-threatening (dyspnea)	Prednisone, 2–3 mg/kg per d; efficient but relapse of dyspnea at each trial to stop treatment	6	2	7	No	14	No	8
5	Female	Periorbital area (inferior canthus)	Functional risk (lacrymal duct closing)	No	2	2			9	Mild recoloration	7
6	Female	Periorbital area (upper eyelid)	Functional risk (pressure on eyeball)	No	6	2			11	No	5
7	Male	Face (inferior eyelid, cheek, and lips)	Functional risk (sucking problems)	No	2	2			6	No	4
8	Male	Upper eyelid and forehead (2 distinct locations)	Functional risk (pressure on eyeball)	No	4	2			8	No	4
9	Male	Upper eyelid and forehead	Functional risk (palpebral occlusion)	Prednisolone, 3 mg/kg per d; moderately efficient	2	2	4	No	9	Mild recoloration	7
10	Female	Forehead	Cosmetic risk	No	4	2			6	Mild regrowth	2
11	Female	Forearm	Local complication (high risk of ulceration)	No	2	2			8	No	6
12	Female	Face (upper eyelid)	Functional risk (astigmatism and amblyopia)	Prednisone, 2 mg/kg per d; stabilization of IH; stopped at 8 mo	18	2			25	No	7
13	Female	Face (glabella)	Cosmetic risk	No	3	2			7	No	4
14	Female	Superior lip	Cosmetic risk	Prednisolone, 2 mg/kg per d; stabilization of IH, esophagitis, and weight stagnation; stopped at 8 mo	25	2			Ongoing		Ongoing
15	Female	Shoulder-blade	Local complication (painful ulceration)	Prednisone, 2 mg/kg per d; inefficient	5	2	6	No	9	No	4
16	Female	Upper eyelid	Functional risk (amblyopia)	2 intralesional corticosteroid treatments; stabilization of IH	41	2			Ongoing		Ongoing
17	Male	Hemiface, neck, and upper airways (nose, pharynx, and glottis)	Life-threatening (laryngeal dyspnea)	Prednisone, 3 mg/kg per d, and adrenaline aerosol treatment; transient efficacy	2	3	3	No	10	No	8
18	Male	Face (nasal tip) and mediastinal area (airway compression)	Life-threatening (dyspnea)	Betamethasone, 0.1 mg/kg per d; worsening dyspnea	9	2	12	No	Ongoing	Snoring after 3 d when stopped at 10 mo	Ongoing
19	Female	Face (periorbital area)	Functional risk (palpebral occlusion)	Prednisone, 3 mg/kg per d; inefficient for IH growth	3	2	12	No	Ongoing		Ongoing
20	Female	Thorax (5% of body area)	Life-threatening (hemodynamic repercussion)	Prednisone, 3 mg/kg per d; stabilization of IH	6	2	6	No	Ongoing		Ongoing
21	Male	Scalp	Cosmetic risk	No	8	2			Ongoing		Ongoing
22	Female	Inferior lip	Cosmetic risk	No	48	2			Ongoing		Ongoing
23	Female	Forearm	Local complication (painful ulceration)	No	3	3			Ongoing		Ongoing
24	Female	Face (nasal tip)	Cosmetic risk	No	3	2			Ongoing		Ongoing
25	Male	Upper eyelid	Functional risk (amblyopia)	No	12	2			Ongoing		Ongoing

TABLE 1 Continued

Patient No.	Gender	Location of IH	Indication for Treatment	Previous Treatment With Corticosteroids	Age at Initiation of Propranolol Treatment, mo	Propranolol Dosage, mg/kg per d	Age at End of Corticosteroid Treatment, mo	Rebound After Corticosteroid Treatment	Age at End of Propranolol Treatment, mo	Relapse After Propranolol Treatment	Duration of Propranolol Treatment, mo
26	Female	Thorax	Local complication (painful ulceration) and cosmetic risk (mammary areola)	No	3	2	Ongoing		Ongoing		Ongoing
27	Male	Forehead and shoulder	Cosmetic risk	No	23	2	Ongoing		Ongoing		Ongoing
28	Female	Back	Local complication (painful ulceration)	No	6	2	Ongoing		Ongoing		Ongoing
29	Female	Parotidal area	Cosmetic risk (face deformation)	No	3	2	Ongoing		Ongoing		Ongoing
30	Female	Face (lower eyelid and upper lip)	Functional risk (palpebral occlusion) and cosmetic risk	No	1	2	Ongoing		Ongoing		Ongoing
31	Female	Inferior lip	Cosmetic risk	No	4	2	Ongoing		Ongoing		Ongoing
32	Male	Periorbital area and scalp	Functional risk (astigmatism) and cosmetic risk (alopecia)	No	6	2	Ongoing		Ongoing		Ongoing

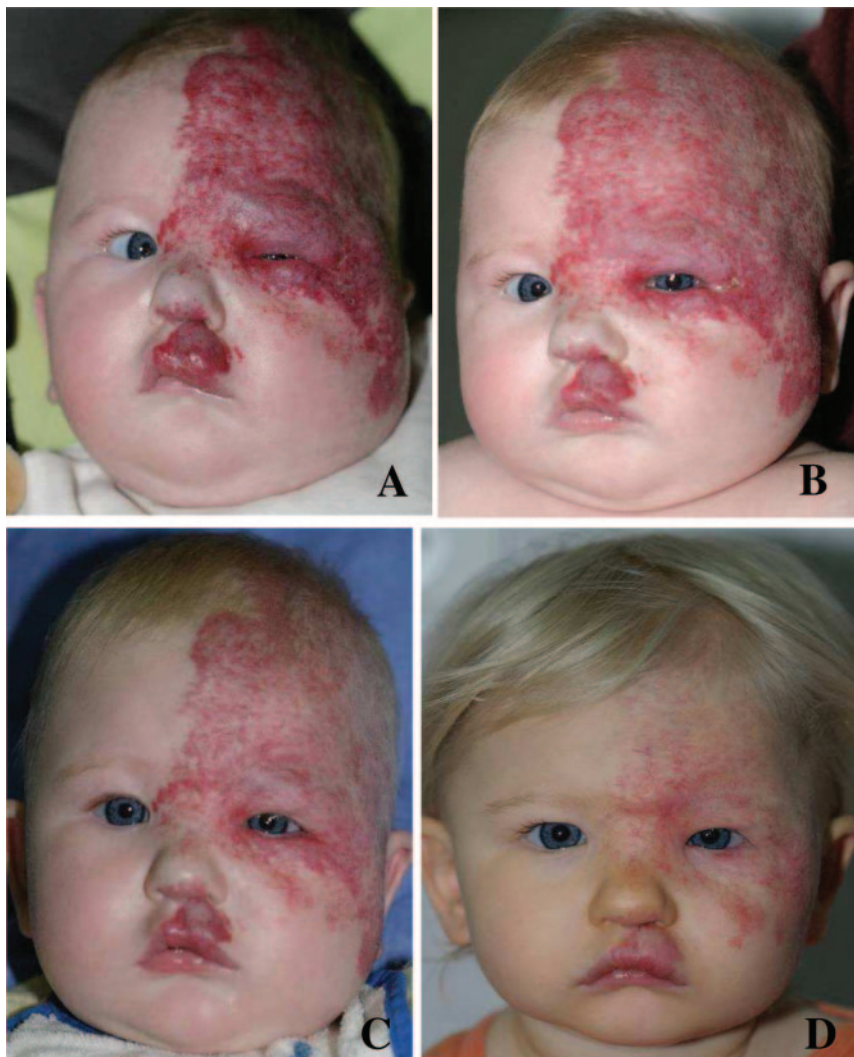

FIGURE 1

Patient 3, with palpebral occlusion. A, Palpebral occlusion at 2 months of age, after 1 week of systemic steroid treatment (2 mg/kg per day) and 1 day before treatment with propranolol. B, Spontaneous eye reopening after 7 days of propranolol treatment at 2 mg/kg per day. C, Further improvement after 2 months of propranolol treatment while prednisone treatment was tapered progressively. D, Residual telangiectases at 12 months of age, after cessation of propranolol treatment.

cacy, because of cardiac indications in 1 case, severe laryngeal dyspnea in 1 case, and painful ulcerations in 2 cases. We monitored blood pressure and heart rate every hour during the first 6 hours of treatment. In the absence of side effects, treatment was continued at home and the child was reevaluated after 10 days of treatment and then every month. Monthly evaluations consisted of clinical and photographic evaluations of the IH and monitoring of treatment compliance and tolerance (heart rate and blood pres-

sure). Body weight was measured for adjustment of dosages. When possible, ultrasound measurements were repeated at day 60 of treatment. For assessment of patients with eyelid involvement, ophthalmologic examinations were repeated as needed.

RESULTS

Data for the 32 children who received propranolol treatment are summarized in Table 1. Twenty-one children were girls; 27 children were 1 to 12 months of age (mean: 4.2 months) for

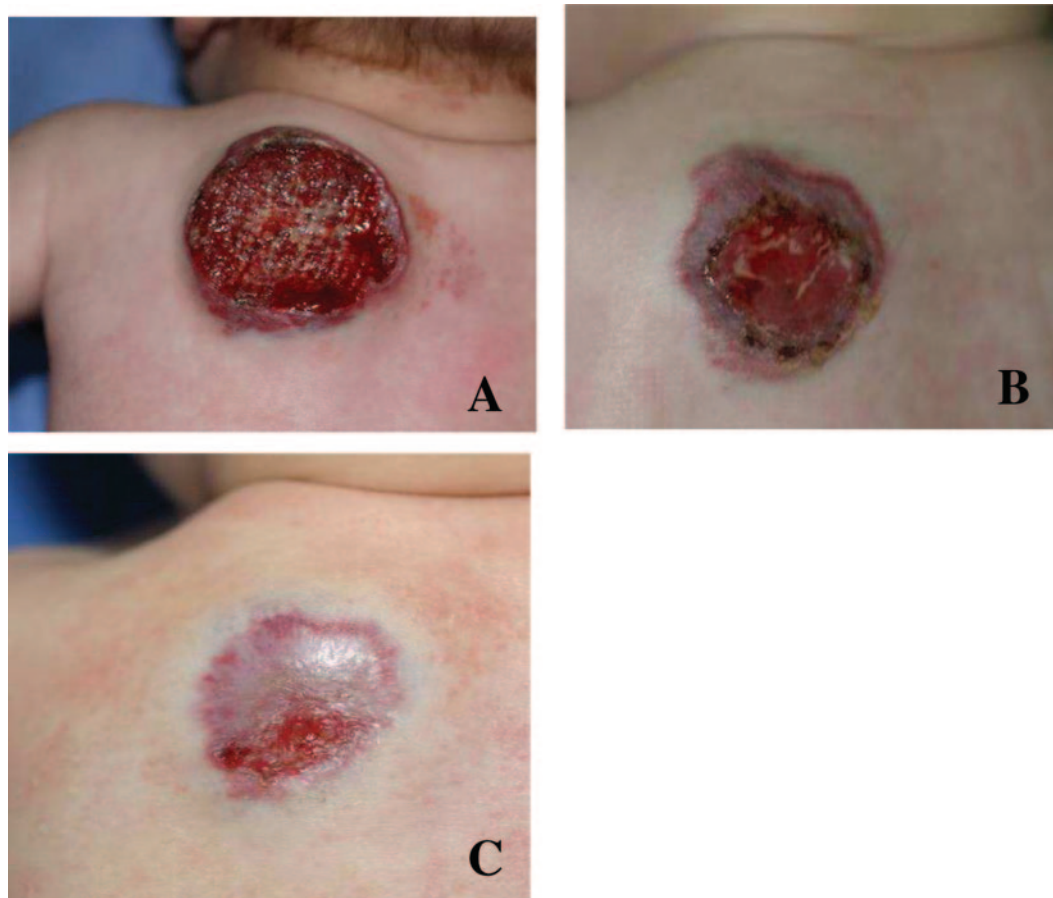


FIGURE 2

Patient 15, with a painful ulcerated IH. Standard treatment with wound care dressings and analgesics was also used. A, At 5 months of age, 1 day before treatment with propranolol. B, Beginning of healing after 2 weeks of propranolol treatment at 2 mg/kg per day. C, Limited ulceration relapse at 8 months of age, after 3 months of propranolol treatment. Complete healing was achieved after the propranolol dosage was increased to 3 mg/kg per day.

early interventions, and 5 were 18 to 48 months of age (mean: 31 months) for late interventions. Early treatment was indicated for severe IHs with life-threatening potential, functional risk, local complications, or cosmetic involvement. Late treatments were indicated to accelerate the natural course of IHs before surgery. No patient with posterior fossa/hemangioma/arterial defect/cardiac problems/eye problems syndrome was included.

With respect to previous treatments, 13 infants had received corticosteroids, with no efficacy or at best stabilization of the lesions. No patient had received interferon or vincristine.

We noted rapid therapeutic effects in all cases. Within 24 hours after the ini-

tiation of propranolol treatment, a change in color from intense red to purple, associated with softening of the lesion on palpation, was noticeable. Symptoms such as dyspnea and hemodynamic compromise regressed within 48 hours, and spontaneous ocular opening was possible within 7 days (Fig 1B). Painful ulcerations healed completely within 2 months (Fig 2). After the dramatic initial response, IHs continued to improve progressively with respect to both color and thickness, as shown in serial photographs (Figs 1 to 4). Ultrasound measurements could be performed for 11 of 32 patients (in the other cases, evaluations were impossible because of location, extension, painful ulceration, or

agitation). At 60 days, ultrasound examinations showed regression in maximal thickness (mean regression: 40%) associated with increased mean resistivity index (from 0.495 before treatment to 0.63 at day 60; +27%; paired Student's *t* test, $P < .0002$ for thickness and $P < .0003$ for resistivity index) (Fig 5). The resistivity index increase is a good indicator of lower vascular activity within the IH.

Corticosteroid treatment administered previously in 13 cases could be discontinued within a few weeks, without rebound, in all cases. Propranolol treatment could be discontinued in 15 cases, at ages ranging from 6 to 14 months for early interventions (mean: 9.4 months), after 2 to 10 months of

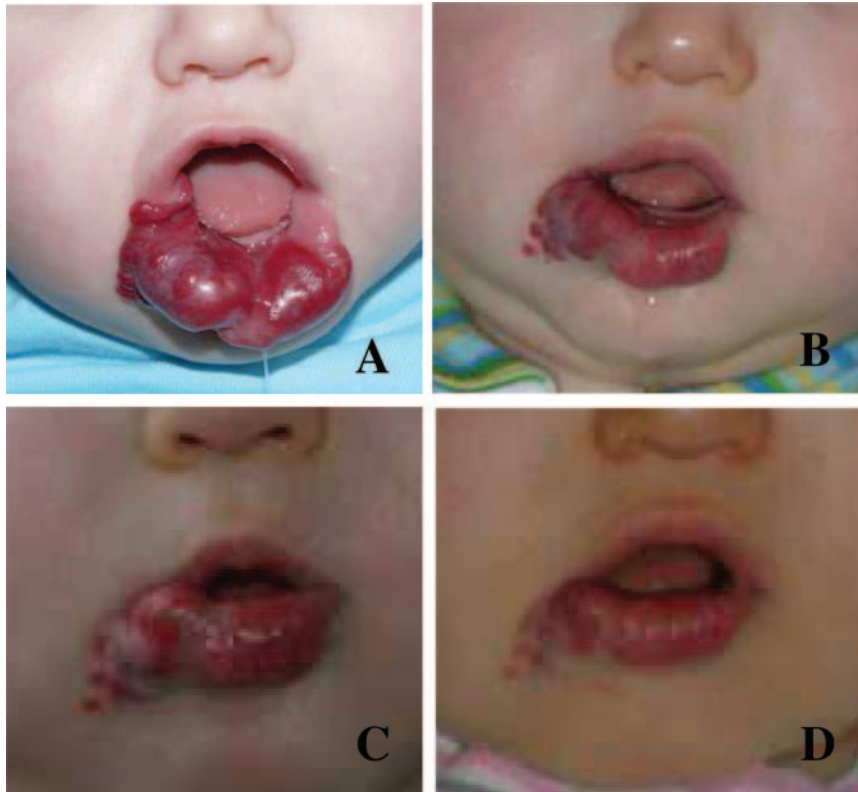

FIGURE 3

Patient 31, at risk of cosmetic disfigurement and ulceration because of a large IH of the inferior lip. A, At 4 months of age, 1 day before treatment with propranolol. B, After 2 months of propranolol treatment at 2 mg/kg per day. C, After 3 months of propranolol treatment at 2 mg/kg per day. D, After 5 months of propranolol treatment at 2 mg/kg per day.

treatment (mean: 6.2 months). At the time of cessation of treatment, the IHs had become nearly flat, with persistence of residual skin telangiectases (Figs 1D and 4D). No relapse was observed in 10 cases (mean age at cessation of treatment: 11.2 months); mild recoloration was noted in 4 cases (mean age: 9 months) and mild regrowth in 3 cases (at 6, 9, and 10 months of age), but these recurrences were mild. Propranolol needed to be administered again because of regrowth in 2 cases, at 9 and 10 months. For the 12 patients with eyelid involvement, good correction of astigmatism or amblyopia was observed at the end of treatment.

A few expected adverse effects were noted during propranolol treatment (Table 2). For 1 patient, blood pressure decreased 3 hours after the first dose,

while the child was sleeping (62/25 mm Hg). This episode resolved spontaneously when the child awoke (91/60 mm Hg), without any therapeutic intervention. One child with wheezing developed 3 months after treatment was initiated and was considered to be related to unrecognized, underlying, allergic asthma, because of the absence of concomitant infection and a personal history of atopic dermatitis. Wheezing stopped within a few days after discontinuation of propranolol treatment.

DISCUSSION

Efficacy

In our study, the efficacy of propranolol reached 100%, with the first effects appearing in the first hours of treat-

ment as changes in color and softening of the lesions. This rapidity of action was especially dramatic in cases involving dyspnea, hemodynamic compromise, or palpebral occlusion. Another remarkable aspect of the results of propranolol treatment is that, not only was IH growth stabilized (which often is achieved with corticosteroids), but the improvement continued until complete involution was achieved, which led to considerable shortening of the natural course of IHs. In line with clinical data, the resistivity index measured after 2 months of treatment was increased significantly and values similar to those found in the late involutive phase of IHs were recorded.¹⁶ Although this effect needs to be confirmed with a larger number of cases, another striking difference from systemic corticosteroid therapy is that we found the same efficacy with respect to color and thickness in IHs that were considered fully developed (late interventions). This rapid involution profile was noted in 5 cases with late introduction of the drug, at variance with the natural course of such IHs. In cases of early intervention, all relapses after treatment cessation occurred before the age of 11 months. This suggests that optimal propranolol treatment must at least cover the proliferative phase of IHs, which usually peaks at 4 months and may last until the age of 8 to 12 months, especially for IHs with subcutaneous components.¹⁷ For late treatments (introduced after the end of the proliferative phase), we think that treatment should be continued empirically until maximal improvement has been achieved.

Possible Mechanism of Action

IHs are composed of a complex mixture of cell types, including a majority of endothelial cells associated with pericytes, dendritic cells, and mast cells. Endothelial cells derived from proliferative IHs are clonal in ori-

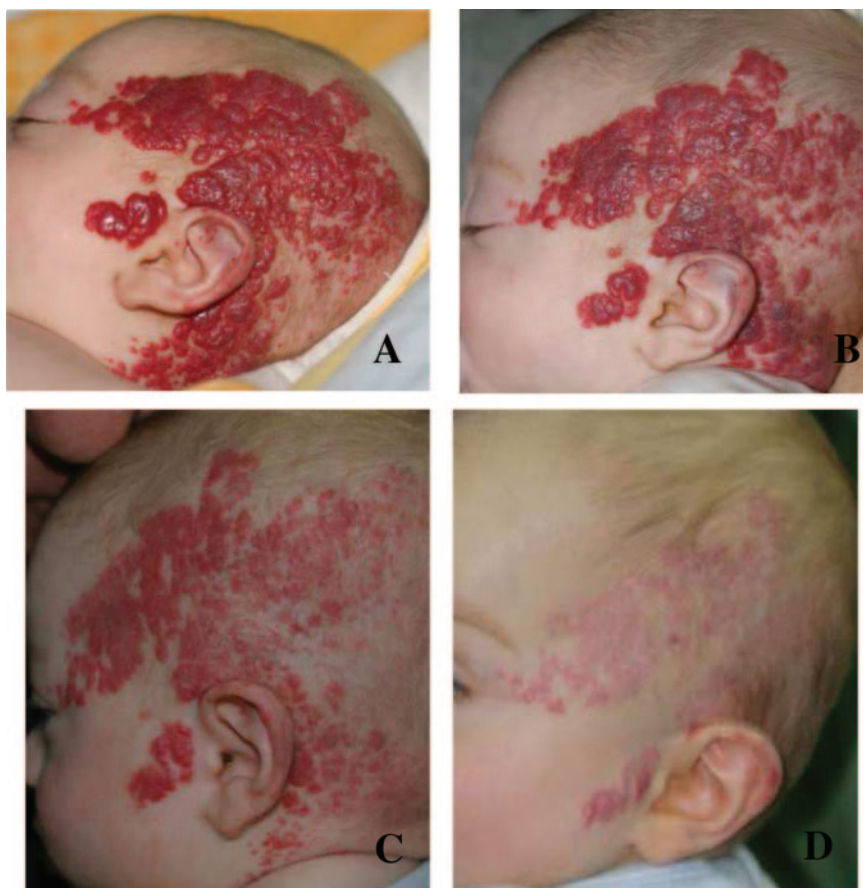

FIGURE 4

Patient 17, with a life-threatening laryngeal IH. The improvement of the cutaneous component should be noted. A, At 2 months of age, 1 day before treatment with propranolol. B, Seven days after initiation of propranolol treatment at 2 mg/kg per day, with a change in color from intense red to purple and palpable softening. C, Further improvement after 2 months of propranolol treatment at 2 mg/kg per day. D, Residual telangiectases at 11 months of age, 1 month after cessation of propranolol treatment.

gin,^{1,18,19} which suggests that IHs arise from the clonal expansion of an endothelial precursor cell, which might be derived from a hematopoietic stem cell.¹ IH endothelial cells are characterized by immunohistochemical positivity for indoleamine-2,3-dioxygenase and LYVE-1 (both of which yield positive results in early-phase IHs and are lost during maturation to a blood vascular phenotype), glucose transporter 1, Lewis Y antigen, FcR11, merosin, chemokine receptor 6, and CD15.¹ Regulators of IH growth and involution are still poorly understood, but it has been demonstrated that, during the growth phase, 2 major proangiogenic factors are involved, that is, basic fibroblast growth factor (bFGF) and vascular en-

dothelial growth factor (VEGF), which are present in situ but also in blood and urine.^{1,20} In addition, in situ hybridization for the VEGF receptor in proliferative IHs showed that VEGF receptors are spread evenly throughout the tumor and are not yet assembled into blood vessels.¹ Histologic studies showed that, during the growth phase of IHs, both endothelial and interstitial cells are in the proliferative stage, as shown by strongly positive MIB-1 staining²¹; during the involution phase, cells exhibit markers of apoptosis in terminal dUTP nick-end labeling assays.²² One hypothesis to explain endothelial cell apoptosis in capillary IHs involves the expression of intercellular adhesion molecule 1 on the cell surface, but

an alternative possibility may be the loss of stimulatory factors such as VEGF.

Propranolol is a nonselective β -adrenergic receptor blocker, and the adrenergic system is the major regulator of cardiac and vascular function. Capillary endothelial cells express β_2 -adrenergic receptors,^{23,24} which modulate the release of nitric oxide, causing endothelium-dependent vasodilatation. We have been able to confirm the presence of β_2 -adrenergic receptors on endothelial cells of IHs and to study their expression at different stages of IH development, as well as in control lesions (M. Cario-André, PhD, C.L.-L., L.J. Nissen, PhD, A.T., F. Majorier, PhD, unpublished data). In addition, β -adrenergic receptors belong to the family of G protein-coupled receptors and, when they are activated by adrenergic catecholamines, they can promote a series of intracellular signal transduction pathways.^{23,24} β -Adrenergic receptor stimulation can induce modifications of signal transduction pathways of angiogenic factors such as VEGF or bFGF.^{23–25} It has been demonstrated that increased cyclic adenosine monophosphate levels inhibit VEGF- and bFGF-induced endothelial cell proliferation. Pharmacologic or β -adrenergic receptor-mediated elevations in cyclic adenosine monophosphate levels block mitogen-induced activation of the mitogen-activated protein kinase signaling pathway, by blocking Raf-1 activity through increased protein kinase A activity. In addition, it has been shown that hypoxia-inducible factor 1 α is expressed on endothelial cells of IHs²⁶ and that, with hypoxia, there is activation of the hypoxia-inducible factor 2 α pathway and subsequent overexpression of VEGF by endothelial cells of IHs.²⁷ Interestingly, a study of the use of β -adrenergic receptor blockers for the treatment of cardiac

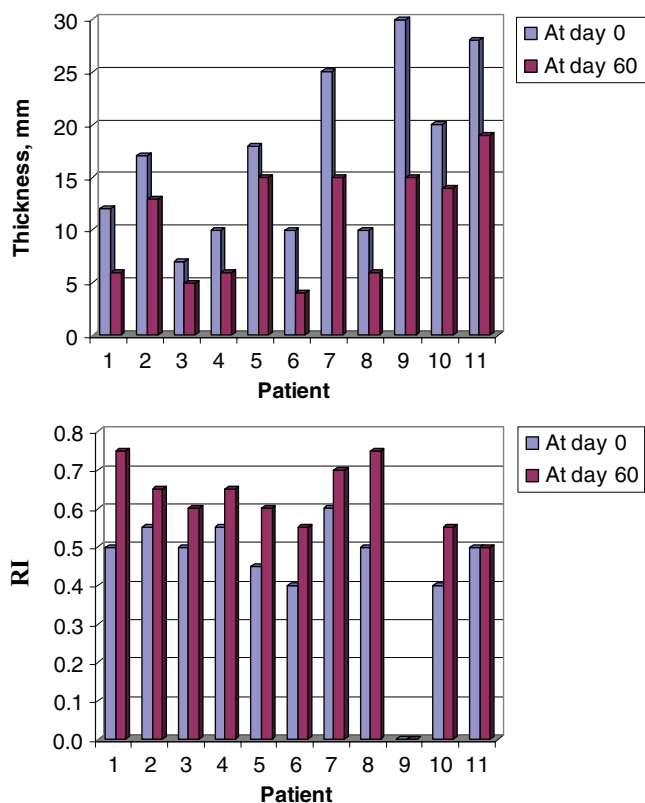


FIGURE 5 Thickness and resistivity index measurements at initiation of treatment (D0) and 2 months later (D60).

hypertrophy revealed that carvedilol reversed levels of both protein and mRNA for hypoxia-inducible factor 1 α and VEGF to baseline values.²⁸ It was demonstrated that β -adrenergic receptor blockade could induce apoptosis of cultured capillary endothelial cells.²⁹

Toxicity

With >40 years of extensive clinical experience with infants and young children, there is no documented case of death or serious cardiovascular morbidity resulting directly from β -adrenergic receptor blocker expo-

sure.³⁰ However, several well-known side effects, such as bradycardia and hypotension, justify close monitoring at the onset of treatment. Bronchospasm is usually seen as a mild exacerbation in patients with underlying reactive airway diseases; before prescription of propranolol, parents should be questioned about previous atopic disease or episodes of wheezing. β -Adrenergic receptor blockers decrease lipolysis, glycogenolysis, and gluconeogenesis, which predisposes patients to hypoglycemia. In addition, they mask some sympathetic hypoglycemic symptoms; it is thus advised to discon-

TABLE 2 Side Effects of Propranolol Treatment (N = 32)

	n
Blood pressure decrease 3 h after first dose	1
Asthma onset	1
Insomnia	2
Agitation	2
Nightmares	1
Profuse sweats	1
Cold hands	1

tinue β -adrenergic receptor blocker treatment temporarily in cases of decreased energy intake. The risk of β -adrenergic receptor blocker-induced hypoglycemia is considered an issue for low birth weight newborns; however, treatment for IHs is rarely indicated in the newborn period. According to our experience, normally fed infants are not at risk.

CONCLUSIONS

In our study, propranolol administered orally at 2 to 3 mg/kg per day had a rapid therapeutic effect in all cases, with color changes and softening appearing within the first hours of treatment. This effect was sustained over the next several weeks, leading to considerable shortening of the natural course of IHs. Moreover, this treatment was well tolerated, with few expected adverse effects being observed, including 1 cessation of treatment because of wheezing. More comparative, randomized studies with a greater number of patients are needed to confirm the safety and efficacy of the drug.

REFERENCES

1. Frieden IJ, Haggstrom A, Drolet BA, et al. Infantile hemangiomas: current knowledge, future directions: proceedings of a research workshop on infantile hemangiomas. *Pediatr Dermatol.* 2005;22(5):383–406
2. Bruckner AL, Frieden IJ. Hemangiomas of infancy. *J Am Acad Dermatol.* 2003;48(4):477–493
3. Margileth AM, Museles M. Cutaneous hemangiomas in children: diagnosis and conservative management. *JAMA.* 1965;194(5):523–526
4. Enjolras O, Gelbert F. Superficial hemangiomas: associations and management. *Pediatr Dermatol.* 1997;14(3):173–179

5. Tanner JL, Dechert MP, Frieden IJ. Growing up with a facial hemangioma: parent and child coping and adaptation. *Pediatrics*. 1998;101(3):446–452
6. Bennett ML, Fleischer AB, Chamlin SL, Frieden IJ. Oral corticosteroid use is effective for cutaneous hemangiomas: an evidence-based evaluation. *Arch Dermatol*. 2001;137(9):1208–1213
7. Enjolras O, Riche MC, Merland JJ, Escande JP. Management of alarming hemangiomas in infancy: a review of 25 cases. *Pediatrics*. 1990;85(4):491–498
8. Shorr N, Seiff SR. Central retinal artery occlusion associated with periocular corticosteroid injection for juvenile hemangioma. *Ophthalmic Surg*. 1986;17(4):229–231
9. Ezekowitz RAB, Phil CBD, Mulliken JB, Folkman J. Interferon alfa-2a therapy for life-threatening hemangiomas of infancy. *N Engl J Med*. 1992;326(22):1456–1463
10. Enjolras O, Breviere GM, Roger G, et al. Vincristine treatment for function- and life-threatening infantile hemangioma [in French]. *Arch Pediatr*. 2004;11(2):99–107
11. Villain E, Denjoy I, Lupoglazoff JM, et al. Low incidence of cardiac events with β -blocking therapy in children with long QT syndrome. *Eur Heart J*. 2004;25(16):1405–1411
12. Fritz KI, Bhat AM. Effect of β -blockade on symptomatic dexamethasone-induced hypertrophic obstructive cardiomyopathy in premature infants: three case reports and literature review. *J Perinatol*. 1998;18(1):38–44
13. Kilian K. Hypertension in neonates causes and treatments. *J Perinat Neonatal Nurs*. 2003;17(1):65–74
14. Léauté-Labrèze C, Dumas de la Roque E, Hubiche T, Boralevi F, Thambo JB, Taïeb A. Propranolol for severe hemangiomas of infancy. *N Engl J Med*. 2008;358(24):2649–2651
15. Frieden IJ, Eichenfield LF, Esterly NB, Geronemus R, Mallory SB. Guidelines of care for hemangiomas of infancy. *J Am Acad Dermatol*. 1997;37(4):631–637
16. Bakhach S, Grenier N, Bèrge J, et al. Color Doppler sonography of superficial capillary hemangiomas [in French] [in French]. *J Radiol*. 2001;82(11):1613–1619
17. Maleville J, Taïeb A, Roubaud E, Sarrat P, Fontan I, Guillet G. Immature cutaneous hemangiomas: epidemiologic study of 351 cases [in French]. *Ann Dermatol Venereol*. 1985;112(8):603–608
18. Boye E, Yu Y, Paranya G, Mulliken JB, Olsen BR, Bischoff J. Clonality and altered behaviour of endothelial cells from hemangiomas. *J Clin Invest*. 2001;107(6):745–752
19. Khan ZA, Boscolo E, Picard A, et al. Multipotential stem cells recapitulate human infantile hemangioma in immunodeficient mice. *J Clin Invest*. 2008;118(7):2592–2599
20. Bielenberg DR, Bucana CD, Sanchez R, Mulliken JB, Folkman J, Fidler IJ. Progressive growth of infantile cutaneous hemangiomas is directly correlated with hyperplasia and angiogenesis of adjacent epidermis and inversely correlated with expression of the endogenous angiogenesis inhibitor, INF- β . *Int J Oncol*. 1999;14(3):401–408
21. Mancini AJ, Smoller BR. Proliferation and apoptosis within juvenile capillary hemangiomas. *Am J Dermatopathol*. 1996;18(5):505–514
22. Razon MJ, Kraling BM, Mulliken JB, Bischoff J. Increased apoptosis coincides with onset of involution in infantile hemangioma. *Microcirculation*. 1998;5(2–3):189–195
23. Iaccarino G, Ciccarelli M, Sorriento D, et al. Ischemic neoangiogenesis enhanced by β_2 -adrenergic receptor overexpression: a novel role for the endothelial adrenergic system. *Circ Res*. 2005;97(11):1182–1189
24. D'Angelo G, Lee H, Weiner RL. cAMP-dependent protein kinase inhibits the mitogenic action of vascular endothelial growth factor and fibroblast growth factor in capillary endothelial cells by blocking Raf activation. *J Cell Biochem*. 1997;67(3):353–366
25. Verhoeckx KC, Doornbos RP, Witkamp RF, van der Greef J, Rodenburg RJ. β -Adrenergic receptor agonists induce the release of granulocyte chemotactic protein-2, oncostatin M, and vascular endothelial growth factor from macrophages. *Int Immunopharmacol*. 2006;6(1):1–7
26. Kleinman ME, Greives MR, Churgin SS, et al. Hypoxia-induced mediators of stem/progenitor cell trafficking are increased in children with hemangioma. *Arterioscler Thromb Vasc Biol*. 2007;27(12):2664–2670
27. Giatromanolaki A, Arvanitidou V, Hatzimichael A, Simopoulos C, Sivridis E. The HIF-2 α /VEGF pathway activation in cutaneous capillary hemangiomas. *Pathology*. 2005;37(2):149–151
28. Shyu KG, Liou JY, Wang BW, Fang WJ, Chang H. Carvedilol prevents cardiac hypertrophy and overexpression of hypoxia-inducible factor-1 α and vascular endothelial growth factor in pressure-overloaded rat heart. *J Biomed Sci*. 2005;12(2):409–420
29. Sommers Smith SK, Smith DM. Beta blockade induces apoptosis in cultured capillary endothelial cells. *In Vitro Cell Dev Biol Anim*. 2002;38(5):298–304
30. Love JN, Sikka N. Are 1–2 tablets dangerous? Beta-blocker exposure in toddlers. *J Emerg Med*. 2004;26(3):309–314

Propranolol for Severe Infantile Hemangiomas: Follow-Up Report

Véronique Sans, Eric Dumas de la Roque, Jérôme Berge, Nicolas Grenier, Franck Boralevi, Juliette Mazereeuw-Hautier, Dan Lipsker, Elisabeth Dupuis, Khaled Ezzedine, Pierre Vergnes, Alain Taïeb and Christine Léauté-Labrèze
Pediatrics 2009;124:e423-e431; originally published online Aug 10, 2009;
DOI: 10.1542/peds.2008-3458

Updated Information & Services	including high-resolution figures, can be found at: http://www.pediatrics.org/cgi/content/full/124/3/e423
References	This article cites 30 articles, 9 of which you can access for free at: http://www.pediatrics.org/cgi/content/full/124/3/e423#BIBL
Subspecialty Collections	This article, along with others on similar topics, appears in the following collection(s): Allergy & Dermatology http://www.pediatrics.org/cgi/collection/allergy_and_dermatology
Permissions & Licensing	Information about reproducing this article in parts (figures, tables) or in its entirety can be found online at: http://www.pediatrics.org/misc/Permissions.shtml
Reprints	Information about ordering reprints can be found online: http://www.pediatrics.org/misc/reprints.shtml

American Academy of Pediatrics

DEDICATED TO THE HEALTH OF ALL CHILDREN™

