

Left heart atrial and ventricular epicardial pacing through a left lateral thoracotomy in children: a safe approach with excellent functional and cosmetic results[☆]

Ali Dodge-Khatami^{a,b,*}, Alexander Kadner^{a,b}, Hitendu Dave^{a,b},
Mariette Rahn^b, René Prêtre^{a,b}, Urs Bauersfeld^c

^aDivision of Congenital Cardiovascular Surgery, University Children's Hospital of Zürich, Zürich, Switzerland

^bDivision of Cardiovascular Surgery, University Hospital, Zürich, Switzerland

^cDivision of Pediatric Cardiology, University Children's Hospital of Zürich, Zürich, Switzerland

Received 21 March 2005; received in revised form 21 June 2005; accepted 29 June 2005; Available online 25 August 2005

Abstract

Objective: Left heart atrial and ventricular epicardial pacing through a left lateral thoracotomy is an alternative approach for lead insertion in children, avoiding venous access complications and right ventricular stimulation, without compromising sporting or musical activities. We analyzed the survival and performance of left atrial and left ventricular epicardial pacing leads, and present mid-term follow-up data. **Methods:** Seventy-five bipolar steroid eluting pacing leads (Medtronic CapSure Epi 4968) were implanted in 41 children, aged 8.6±5.1 years. Pacing systems included 34 DDDR and 7 VVIR. Pacing leads were inserted through a muscle-sparing left lateral thoracotomy, and sutured to the left atrial appendage or atrium, and to the left ventricle. The generators were buried behind the abdominal muscles or between the thoracic muscle layers. Congenital heart disease with previous cardiac surgery was present in 25 children. Indications for pacing were post-operative heart block ($n=14$), sinus node disease ($n=13$), congenital heart block ($n=9$), and various ($n=5$). Threshold values and measured data were obtained at 6-month intervals. The mean follow-up was 3.8±2.9 years. **Results:** There was no mortality or major morbidity, with excellent functional and cosmetic results. Lead survival was 94 and 86% for atrial leads, and 97 and 86% for ventricular leads, at 1 and 5 years, respectively. There were five reoperations for lead fracture ($n=2$), insulation break ($n=1$), oversensing ($n=1$), and infection ($n=1$). Device reprogramming was required in three instances. In the absence of acute lead failure, mid-term follow-up shows very satisfactory and stable lead performance. **Conclusions:** Left heart atrial and ventricular epicardial pacing leads inserted through a left lateral thoracotomy demonstrate a high probability of survival, with favorable pacing characteristics, and optimal sensing thresholds at mid-term follow-up. Epicardial left heart pacing is reliable, and easy access can be achieved through a cosmetic and functional muscle-sparing left lateral thoracotomy.

© 2005 Elsevier B.V. All rights reserved.

Keywords: Epicardial pacing; Left heart; Thoracotomy

1. Introduction

Arrhythmia in children may be congenital, or a consequence of structural congenital heart disease and related surgery. Patients can therefore present with previous sternotomy incisions, incisions into the heart chambers, or be free of prior surgery. Access for implantation of a pacemaker system will involve either the transvenous approach, or an epicardial one, achieved through a sternotomy, a subxyphoid incision, or a thoracotomy.

In adults and historically in children, transvenous pacing lead insertion was universal, and provided the best mid and long-term results. In infants and children, however, disadvantages of transvenous systems relating to the infra-clavicular pacing generator include an unattractive visible scar, an anterior chest wall position which puts the generator at risk for trauma, as well as functional limitations with regards to certain musical or sporting activities. Other concerns or contraindications pertaining to transvenous leads are the risks for venous thrombosis or superior caval obstruction, the presence of intra-cardiac shunts, as well as the lack of anatomic access in patients with single ventricle physiology and prior surgery [1]. These factors and others led to increased popularity of epicardial pacing systems, which have been substantially improved in the recent years, owing greatly to steroid-eluting technology. Epicardial leads currently enjoy performance similar to, or even superior to their venous counterparts. At our institution, initial encouraging results with epicardial pacing systems have led us to prefer this access, which has become routine, even

[☆] Presented at the 40th Annual Meeting of the Association for European Paediatric Cardiology, Copenhagen, Denmark, May 19, 2005.

* Corresponding author. Address: Division of Congenital Cardiovascular Surgery, University Children's Hospital of Zürich, Steinwiesstrasse 75, CH-8032 Zürich, Switzerland. Tel.: +41 1 2668020; fax: +41 1 2668021.

E-mail address: ali.dodge-khatami@kispi.unizh.ch (A. Dodge-Khatami).

in patients without prior surgery. Increasingly, evidence is growing to support the advantages of left heart stimulation as opposed to right heart stimulation [2-4], leading our group to implant left heart pacing systems. We report our experience with left heart pacing through a mini-left lateral thoracotomy in children, and dwell upon the cosmetic and functional advantages.

2. Material and methods

Between 1996 and 2004, 41 consecutive patients underwent pacemaker device and lead insertion through a muscle-sparing mini-left lateral thoracotomy (Fig. 1). Mean age was 8.6 ± 5.1 years (range 7 days to 17.4 years). Indications for pacing included post-operative complete heart block ($n=14$), sinus node dysfunction ($n=13$), complete congenital heart block ($n=9$), and various ($n=5$) diagnoses such as long QT syndrome and acquired atrio-ventricular block. Previous sternotomy for surgical correction of congenital heart disease was present in 25 children. There were no children with a prior left thoracotomy. Single ventricle physiology was present in 11 patients, and the pacing leads were therefore placed on the systemic ventricle, independently of left or right morphology.

A vertical or horizontal incision was made in the mid-axillary line, parallel to the border of the grand dorsalis muscle or across it at the 4th intercostal space, respectively. The subcutaneous tissue was generously undermined, the grand dorsalis muscle was retracted posteriorly, a passage was dissected between and parallel to the fibers of the serratus anterior muscle, and the 4th intercostal space opened. The pericardium was opened 2 cm posterior and parallel to the phrenic nerve. First, bipolar steroid-eluting pacing leads (Medtronic CapSure Epi 4968) were sutured to the left ventricle (LV) and the left atrial appendage with non-absorbable sutures. It is important to place the atrial leads away from the ventricular surface (Fig. 2, insert) to avoid far-sensing and cross-ventricular stimulation. The lateral free wall of the left ventricle was selected for lead placement, corresponding to an area between the left anterior descending coronary artery and the diagonal coronary branches, preferably as far away from the left atrial appendage as possible.

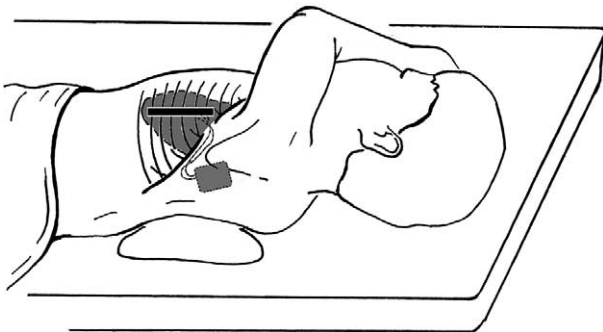


Fig. 1. Illustration depicting the left lateral thoracotomy incision, and position of the electrodes on the left heart structures, with pacemaker battery in place.

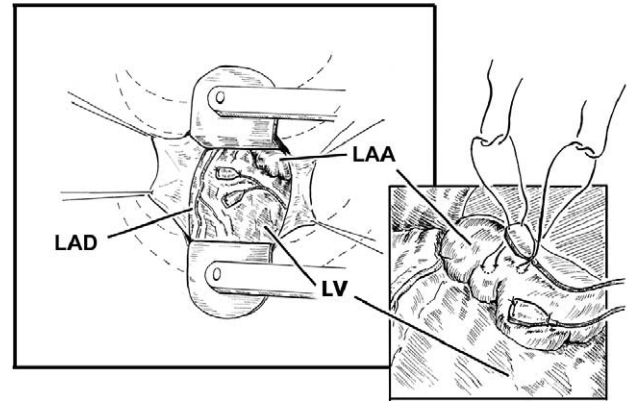


Fig. 2. Detail of thoracotomy through the 4th left intercostal space with the pericardium opened posterior to the phrenic nerve. Electrodes are sutured to the left atrial appendage (insert) and the left ventricular lateral wall, between the left anterior descending coronary artery and the diagonal coronary branches. LV, left ventricle; LAA, left atrial appendage; LAD, left anterior descending coronary artery.

Pacing systems were then connected to the leads, and included 34 DDR and 7 VVIR generators. The 13 patients with sinus node disease were all patients after Fontan palliation for single ventricle physiology or after Senning correction for complete transposition of the great arteries, and received DDD generators. This allowed for better hemodynamics with adequate atrio-ventricular timing in patients with concomitant anti-arrhythmic medication. The pacer generators were buried either in the abdominal rectus muscle sheath ($n=25$), between the thoracic muscles ($n=13$), or in the peritoneal cavity ($n=3$). Early on, we inserted the pacemaker generator in the sheath of the left abdominal rectus muscle, which required a separate skin incision and tunneling of the pacer leads parallel to the ribs to reach the generator pocket. In larger children, we later changed to inserting the pacemaker battery through the same thoracotomy incision between the various muscle compartments of the left shoulder region, thus avoiding a second incision, without causing shoulder discomfort or functional incapacity. Most often, a position underneath the grand dorsalis muscle/scapula and therefore on the serratus anterior muscle or ribcage provided the most comfortable fit. Intraperitoneal positioning of the pacemaker is still performed in neonates and infants, whose scapular muscle apparatus is insufficient to comfortably harbor a generator, however small. Generators were secured to adjacent muscle with a non-absorbable suture. We did not elect to position the generator in the lumbar area, although this technique is possible in neonates.

In the absence of lead complications, follow-up was performed routinely every 6 months with full lead measurements and generator interrogation. Rest and stress echocardiography were systematically performed at the time of pacemaker interrogation, looking specifically at ventricular function, dimensions, and eventual wall motion abnormalities. No physical restrictions were suggested to the patients besides avoiding heavy contact sports. Follow-up was

complete at a mean of 3.8 ± 2.9 years (range 1 month to 9.7 years).

3. Results

There was no surgical mortality or major morbidity. All children recovered left shoulder and arm function within days, and cosmetic results were outstanding (Fig. 3). At last follow-up in those patients with pacer generators left between the thoracic muscle layers, no child complained of functional impairment or discomfort. Lead characteristics at 1 and 5 years follow-up are shown in Table 1.

At 1 and 5 years, atrial lead survival was 94 and 86%, respectively, and ventricular lead survival was 97 and 86%, respectively. Reoperations for new lead placement were required in five children: two for lead fracture, one for insulation break, one for oversensing, and one pacing system infection. Reprogramming was done in three devices, for atrial lead dysfunction in one child, for pacing failure in another, and for ventricular lead fracture in the last. On serial echocardiographic follow-up, there was no sign of global or regional LV dysfunction, and ventricular dimensions remained unchanged.

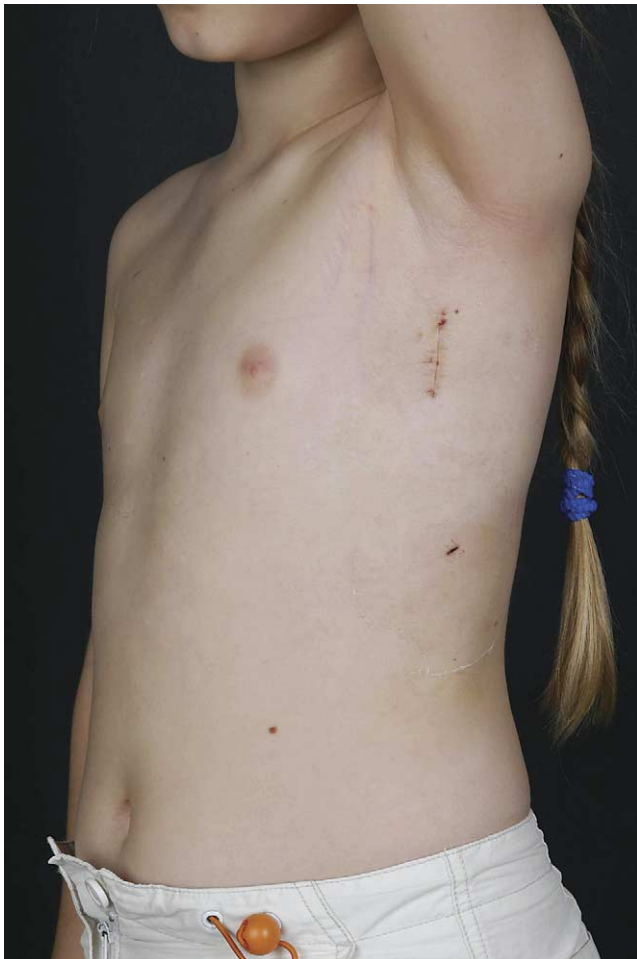

Fig. 3. Post-operative photography of the mini-lateral left thoracotomy incision from a lateral view.

Table 1
Pacing lead characteristics at 1 and 5 years follow-up

	1 year	5 years	
Atrial impedance Ohm	636 ± 87	709 ± 103	$P=0.01$
Atrial threshold V at 0.5 ms	1.1 ± 0.6	1.3 ± 0.5	ns
Atrial sensing mV	3.4 ± 1.5	3.7 ± 1.7	ns
Ventricular impedance Ohm	656 ± 168	716 ± 194	ns
Ventricular threshold V at 0.5 ms	1.3 ± 0.9	1.3 ± 0.7	ns
Ventricular sensing mV	10.1 ± 4.8	10.8 ± 4.4	ns

4. Discussion

Traditionally, transvenous leads with subsequent right ventricular (RV) pacing have been the preferred mode of stimulation not only in adults, but also in children. However, this approach is not devoid of undesirable complications, and specific considerations need to be taken into account for the pediatric population. Small and young patients will require pacing during an entire lifetime, and lead extraction and replacement is extremely hazardous or impossible [1]. Therefore, these patients will accumulate leads in their venous system, with the risk of caval thrombosis and obstruction. In addition, unfavorable venous anatomy or prior surgery may preclude access to the right-sided heart chambers, such as that seen after cavo-pulmonary anastomosis, total cavo-pulmonary connection, tricuspid valve replacement, or the Senning and Mustard operations [1]. With these concerns in mind, we find the transvenous approach suboptimal, and endorse the epicardial mode of stimulation.

There is increasing evidence that sequential right atrial-/right ventricular pacing leads to unfavorable hemodynamics, dyssynchrony, and remodeling for both ventricles, mostly so for the left ventricle, in the form of LV dilatation and asymmetrical hypertrophy [5]. Despite physiologic heart rates and atrio-ventricular synchrony achieved by dual-chamber right heart stimulation, exercise capacity is lower, when compared to healthy controls [5]. The apical RV site, traditionally used for endocardial pacing, leads to loss of contraction coordination in LV segments and increased mitral valve regurgitation, resulting in decreased diastolic and systolic performance and increased cardiac energy requirement [5]. Confirming these findings, Tantengco et al. found impaired regional wall motion abnormalities, namely paradoxical septal motion with septal bulging, and Doppler flow-derived indexes of LV systolic and diastolic function in young patients after RV apical pacing, as compared to healthy controls [6]. Evidence of dilated cardiomyopathy in infants associated with dual-chamber right heart pacing has recently been published [7], which was improved after either left ventricular pacing or reprogramming the pacemaker 'off', to allow normal intrinsic conduction. It is stipulated that left ventricular mechanical dyssynchrony and high heart rates result, when pure DDD right heart stimulation is performed early in life [7]. In adult patients with chronic atrial fibrillation undergoing complete atrio-ventricular junction ablation and ventricular pacing, Puggioni et al. found an increase in ejection fraction and reduced mitral valve regurgitation with LV pacing, as compared to RV pacing [2]. In patients with end-stage heart failure, left ventricular pacing has shown superior

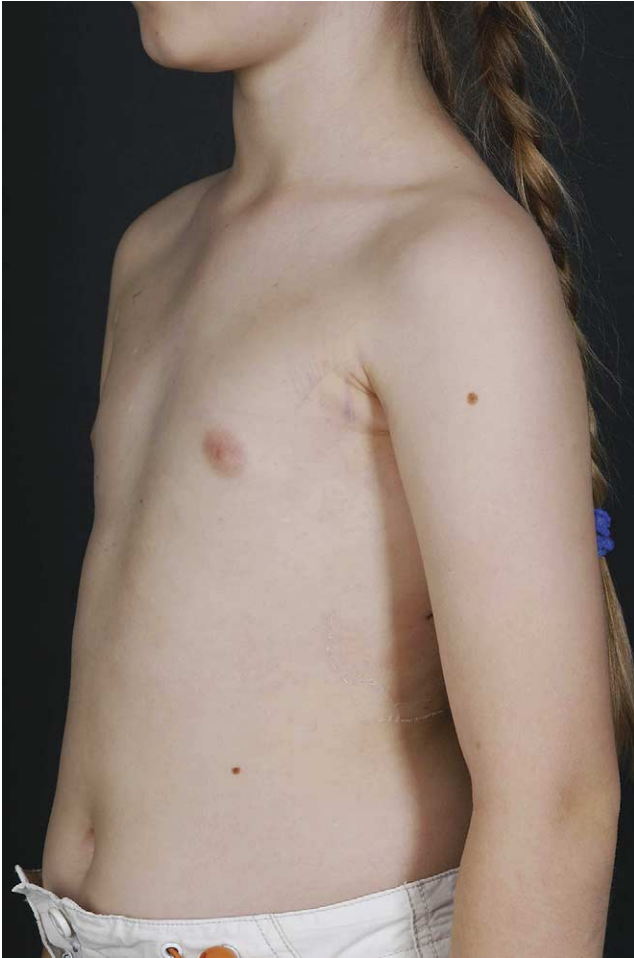

Fig. 4. Photography of the same patient with the arm adducted; the incision is virtually invisible.

results [4] when compared to RV pacing, as determined by blood pressure, pulmonary capillary wedge pressure, and V-wave appearance [3].

According to the study by Vanagt et al., the left ventricular apex is a better site than the lateral free wall, resulting in synchronous activation of the LV circumference [8]. This pacing site is accessible on a beating heart from a left lateral thoracotomy, although we did not try this, and used the lateral free wall of the LV instead, and found no LV dysfunction on serial echocardiographic follow-up. Future studies or a trial in our own center may help to elucidate a difference or advantage amongst the two LV pacing sites.

Besides the increasingly documented electrophysiologic advantage of pacing the left heart structures as opposed to the right heart ones [2-4], a potential practical advantage lies purely in the surgical approach with a left thoracotomy. In a child who has already undergone surgery for correction of a congenital heart defect through a midline sternotomy needing a pacemaker system, multiple adhesions may exist between the heart and the chest wall, with inherent risks of bleeding during re-entry. Also, the adhesions represent thickened scar tissue with high tissue resistance to electrical current, often yielding unsatisfactory pacing characteristics when leads would need to be secured, potentially leading to

early pacemaker battery depletion. These suboptimal conditions seem reduced when approaching through a left thoracotomy, in that the risk of bleeding during re-entry is minimalized, and scar tissue hardly ever forms in the region of the left atrial appendage and the left ventricular lateral wall, allowing for safer surgery and durable pacing performance. In our experience, it was always possible to identify and avoid the coronary arteries so as to safely suture the pacing leads, and find unscarred epicardium with excellent pacing characteristics. We had no patients with a prior left thoracotomy approach for the repair or palliation of congenital heart disease. In this particular subgroup, performing a repeat left thoracotomy for pacemaker insertion can be difficult and maybe contraindicated, as re-entry bleeding and the absence of unscarred epicardium would be relevant issues.

Finally, as illustrated in Fig. 3, the short muscle-sparing left lateral thoracotomy resulted in excellent cosmetics, with a short incision which is fully covered by the adducted left arm (Fig. 4). We have used this same incision, but on the right side, to perform atrial and ventricular septal defect closure on cardiopulmonary bypass in 25 children with excellent cardiac, functional, and general cosmetic results [9].

4.1. Study limitations

Although performed in a consecutive series of patients with standardized surgery aimed at evaluating a surgical approach and its impact on pacemaker lead performance, the results of our study are limited by the retrospective nature of its design. Also, there is no control group having undergone pacemaker system implantation through a different incision.

5. Conclusions

We found insertion of a dual-chamber epicardial pacemaker system through a left lateral thoracotomy to be a reliable and reproducible surgical approach, with particular advantages in patients with prior repair of congenital heart defects through a sternotomy and scarred epicardium. In this redo setting, safety in re-entry was enhanced, and pacing site availability was always encountered. Stimulation of left heart chambers provided optimal pacing performance in the immediate post-operative period with improvement of lead characteristics at mid-term follow-up. Finally, the muscle-sparing mini-incision provided excellent cosmetic and functional results, allowing near unrestricted physical activities.

References

- [1] Dodge-Khatami A, Johnsrude C, Backer CL, Deal BJ, Strasberger J, Mavroudis C. A comparison of steroid-eluting epicardial versus transvenous pacing leads in children. *J Card Surg* 2000;15:323-9.
- [2] Puggioni E, Brignole M, Gammage M, Soldati E, Bongiorno MG, Simantirakis EN, Vardas P, Gadler F, Bergfeldt L, Tomasi C, Musso G,

- Gasparini G, Del Rosso A. Acute comparative effect of right and left ventricular pacing in patients with permanent atrial fibrillation. *J Am Coll Cardiol* 2004;43:234-8.
- [3] Blanc J-J, Etienne Y, Gilard M, Mansourati J, Munier S, Boschat J, Benditt DG, Lurie KG. Evaluation of different ventricular pacing sites in patients with severe heart failure. *Circulation* 1997;96:3273-7.
- [4] Lupi G, Brignole M, Oddone D, Bollini R, Menozzi C, Bottoni N. Effects of left ventricular pacing on cardiac performance and on quality of life in patients with drug refractory heart failure. *Am J Cardiol* 2000;86:1267-70.
- [5] Thambo J-B, Bordachar P, Garrigue S, Lafitte S, Sanders P, Reuter S, Girardot R, Crepin D, Reant P, Roudat R, Jaïs P, Haïssaguerre M, Clementy J, Jimenez M. Detrimental ventricular remodeling in patients with congenital complete heart block and chronic right ventricular apical pacing. *Circulation* 2004;110:3766-72.
- [6] Tantengco MVT, Thomas RL, Karpawich PP. Left ventricular dysfunction after long-term right ventricular apical pacing in the young. *J Am Coll Cardiol* 2001;37:2093-100.
- [7] Janousek J, Tomek V, Chaloupecky V, Gebauer RA. Dilated cardiomyopathy associated with dual-chamber pacing in infants: improvement through either left ventricular cardiac resynchronization or programming off allowing intrinsic normal conduction. *J Cardiovasc Electrophysiol* 2004;15:470-4.
- [8] Vanagt WY, Verbeek XA, Delhaas T, Mertens L, Daenen WJ, Prinzen FW. The left ventricle apex is the optimal site for pediatric pacing: correlation with animal experience. *PACE* 2004;27:837-43 [Pt II].
- [9] Prêtre R, Kadner A, Dave H, Dodge-Khatami A, Bettex D, Berger F. Right axillary incision: a cosmetically superior approach to repair a wide range of congenital cardiac defects. *J Thorac Cardiovasc Surg* 2005;130:277-81.