



Understanding congenital heart disease

Nick Barnes, Nick Archer*

Department of Paediatric Cardiology, John Radcliffe Hospital, Headley Way,
Headington, Oxford OX3 9DU, UK

KEYWORDS

Chest X-ray;
Congenital heart
disease;
Electrocardiogram;
Pathophysiology

Abstract This article outlines the relevance of cardiovascular pathophysiology in the clinical presentation and management of the most common congenital heart defects and introduces clinically important aspects of the fetal and perinatal circulations. Explanation of how the results of basic investigations, such as the electrocardiogram and the chest X-ray, relate to pathophysiology is also presented.
© 2005 Elsevier Ltd. All rights reserved.

Introduction

A knowledge of cardiovascular pathophysiology, considered in conjunction with clinical assessment, and the results of widely available non-specialist investigations, such as an electrocardiogram (ECG) and chest X-ray (CXR), are useful in the management of many common or typical problems encountered in children with heart disease. Examples include the newborn with Down syndrome and a normal cardiopulmonary examination, 'spells' in infants with tetralogy of Fallot, and a left-to-right shunt lesion (e.g. ventricular septal defect) in a young infant.

Investigations

The chest X-ray

An awareness of the normal radiographic position and shape of the heart and mediastinum

can make the CXR a useful investigation in CHD (Fig. 1).

The electrocardiogram

Reading and interpreting the ECG correctly, including the changes that occur with increasing age, is only possible with a comprehension of normal, and this is covered in standard texts.^{1,2}

Congenital heart disease can be divided into the following groups:

- left-to-right shunt lesions
- obstructive lesions
- regurgitant lesions
- cyanotic lesions.

Following a description of the clinically important aspects of fetal and perinatal circulation, which are useful in understanding the pathophysiology of CHD, we discuss the most common lesions in each of the above groups and outline the 'core' pathophysiology for each, emphasizing its relevance to clinical practice.

*Corresponding author. Tel.: +44 1865 221495;
fax: +44 1865 857958.

E-mail address: nick.archer@orh.nhs.uk (N. Archer).

Fetal and perinatal circulation

Fetal blood flow

The course of the fetal circulation³ determines the dimensions of fetal cardiac chambers. The right and left ventricles (RV and LV) handle proportionally 55% and 45% of the cardiac output, resulting in the RV being the larger of the two and explaining why the neonatal ECG shows a predominant RV force. The pulmonary artery branches are proportionally smaller than the main pulmonary artery (MPA), as only 15% of ventricular output passes to the lungs. This difference in size (relative peripheral pulmonary stenosis) can produce acceleration of blood from the MPA to left and right pulmonary arteries and a murmur in early infancy.⁴

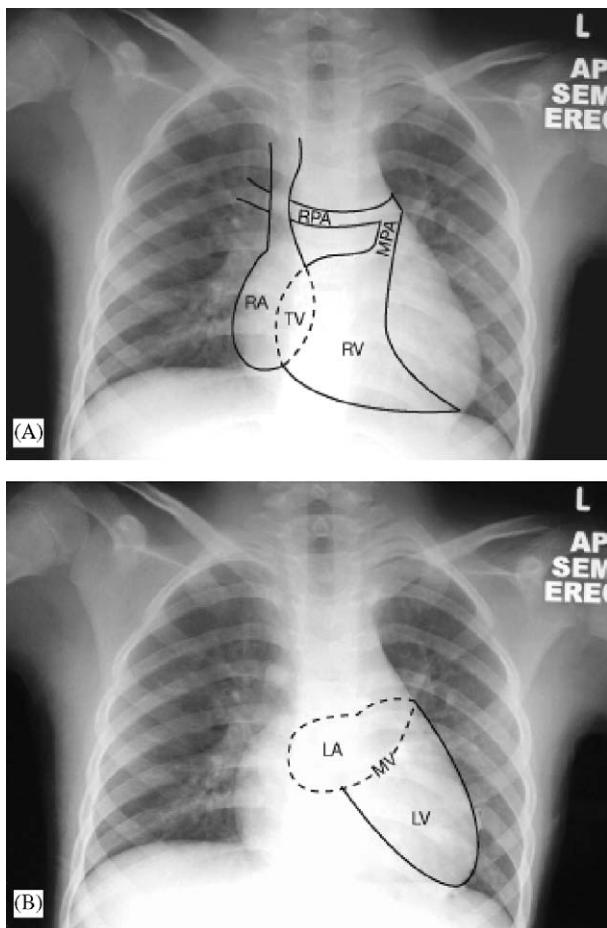


Figure 1 (A) Radiographic position of normal right heart structures. RA, right atrium; TV, tricuspid valve; RV, right ventricle; MPA, main pulmonary artery; LPA left pulmonary artery. (B) Radiographic position of normal left heart structures. LA, left atrium; MV, mitral valve; LV, left ventricle.

The perinatal circulation

After birth, removal of the low-resistance placental circulation increases the systemic vascular resistance and is associated with closure of the ductus venosus. Lung inflation sets in motion a sequence of events:

- The pulmonary vascular resistance (PVR) falls, pulmonary artery (PA) pressure falls and pulmonary blood flow (PBF) increases.
- Increased PBF raises pressure in the left atrium (LA) to above the pressure in the right atrium (RA), producing functional closure of the foramen ovale (or, not infrequently, a short-lived left-to-right shunt).
- Increased arterial oxygenation promotes closure of the ductus arteriosus (DA).

The precise timing of the fall in PVR and closure of the PDA influence the natural history of many congenital heart lesions.

Pulmonary vascular resistance

An initial reduction in PVR at birth is followed by a more gradual fall over 6–8 weeks to a level found in adult life. Any condition disrupting postnatal pulmonary vascular maturation (e.g. respiratory disease, acidaemia, hypoxia, structural cardiac abnormalities) can slow this process. Children with large left-to-right shunt lesions do not usually become symptomatic and might not have impressive murmurs until after the first month of life, when the fall in PVR begins to allow significant left-to-right shunting.

The ductus arteriosus

By virtue of vascular smooth muscle constriction, the ductus closes in the majority of cases by 3 days of age.⁵ Oxygen is the most potent stimulus to closure, although this response can be blunted in the extremely preterm neonate. Locally produced and circulating prostaglandins also influence fetal and postnatal ductal patency and ductal closure can be promoted in preterm neonates with prostaglandin synthetase inhibitors such as indomethacin and ibuprofen. Ductal closure precipitates clinical deterioration in a variety of lesions such as obstructed right heart, transposition of the great arteries with intact ventricular septum and obstructed left heart (see below).

Practice points

- The right ventricle is dominant in fetal life
- The reduction of PVR over the first 8 weeks of life influences the presentation of some congenital heart lesions
- Ductal closure, usually complete by day 3 of life, can precipitate clinical deterioration in a variety of lesions

Left-to-right shunt lesions

Secundum atrial septal defect

Shunting is typically left-to-right across an isolated secundum atrial septal defect (ASD), the magnitude determined by the size of the defect and the relative compliance of RV and LV. The greater compliance of the relatively lower-pressure RV favours left-to-right shunting, with resultant increased right heart, pulmonary artery and pulmonary venous blood flow. The left heart is not significantly enlarged because increased flow to the LA passes through the ASD to volume-load the right heart. This alteration in normal haemodynamics is reflected both clinically and on ECG and CXR.

The heart murmur of ASD is heard over the pulmonary valve area in systole, reflecting increased flow through the valve. Increased RV inflow during diastole produces a diastolic murmur best heard over the tricuspid valve area. The left-to-right shunt across the atrial septum itself is silent. The shunt diminishes the fluctuation in RV output normally brought about by respiration, resulting in delayed closure of the pulmonary valve and wide fixed splitting of S₂. Volume loading of the RV results in an rSR pattern in the right chest leads sometimes termed (but probably incorrectly) right bundle branch block. Fig. 2 illustrates a typical CXR.

ASD is virtually never symptomatic in infancy and only rarely causes major symptoms in early childhood.

Ventricular septal defect

The magnitude of left-to-right shunt is determined by the size of the defect and the level of PVR. Shunting across small defects is limited by defect size rather than PVR. Larger defects offer little

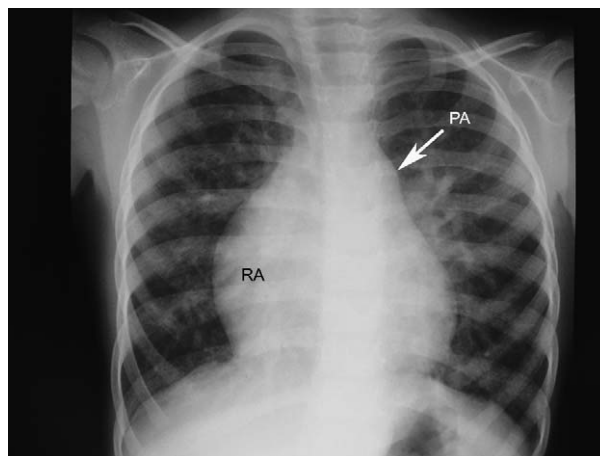


Figure 2 Chest X-ray (CXR) typical of atrial septal defect (ASD). Right atrial (RA) and right ventricular (RV) hypertrophy, with enlargement of the pulmonary artery (PA) and increased pulmonary vascular markings.

local resistance and the degree of shunting is dependent on the PVR, a lower PVR facilitating a greater shunt (Fig. 3). A familiar clinical picture is the infant with a large ventricular septal defect (VSD) who develops a heart murmur and is found to be tachypnoeic and have hepatomegaly at around 4–6 weeks of age, the time by which PVR has fallen to a level that allows significant left-to-right shunting.

In a moderate-sized VSD the left heart is volume-loaded, as increased pulmonary blood flow (which elevates PA pressure and therefore P₂ intensity) eventually returns to the heart. The mitral valve is subject to increased blood flow, and produces a mid-diastolic apical rumble. LV volume-loading is reflected in the ECG, with LVH characteristic.

A large VSD results either in a greater shunt, or in failure of the PVR to fall to a normal level, causing biventricular hypertrophy apparent on ECG and CXR.

Patent ductus arteriosus

The pathophysiology of patent ductus arteriosus (PDA) is similar to that of VSD. When the PDA is small, the magnitude of the left-to-right shunt is determined by ductus length, diameter and tortuosity; with a larger duct the size of the PVR is more influential when a significant pressure gradient exists between aorta and pulmonary artery throughout the cardiac cycle. Continuous shunting produces the characteristic continuous murmur best heard beneath the left clavicle. Significant shunting in the early weeks of life in term infants is unusual because a high PVR limits the development of a large aorto-pulmonary pressure gradient. After

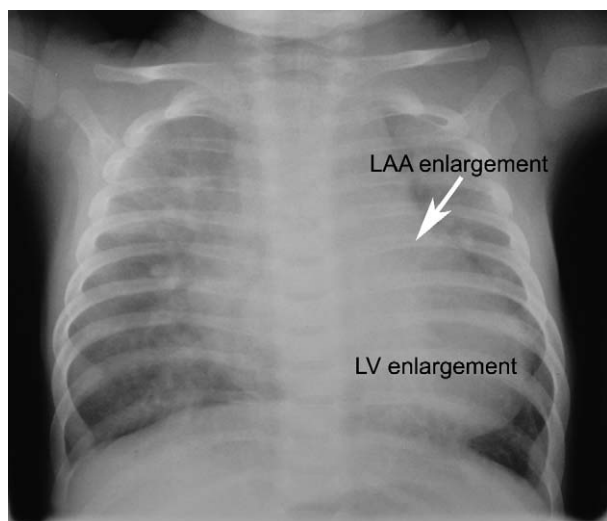


Figure 3 Left atrial (LA) appendage and left ventricular (LV) enlargement with increased pulmonary vascular markings, typical chest X-ray (CXR) findings of a non-restrictive ventral septal defect (VSD).

this time left heart volume-loading develops with chamber and vessel enlargement as in VSD.

Atrioventricular septal defects

Partial (ostium primum ASD) defects behave like secundum ASD in terms of shunt physiology, but may additionally have important atrioventricular valve regurgitation (as a result of valve clefts) that produces symptoms in infancy. Complete AVSDs behave in the manner described above for VSD. Both lesions are characterized by the presence of a 'superior' mean frontal QRS axis on ECG as a result of a primary developmental abnormality of the conduction system (Fig. 4).

Eisenmenger's syndrome

If left unchecked, any of the left-to-right shunt lesions can result in pulmonary vascular disease and right-to-left shunting with cyanosis. The timing of onset is variable, developing in late childhood or early adolescence with AVSD, VSD and PDA, and later—if at all—in ASD.

Practice points

- The timing of symptoms attributable to left-to-right shunt lesions can be influenced by PVR
- ASD results in right-heart volume-loading and is virtually never symptomatic in infancy

- PDA, VSD and complete AVSD result in left-heart volume loading and commonly produce symptoms in infancy

Obstructive lesions

Coarctation of the aorta (COA)

A minority of patients with coarctation present collapsed in the neonatal period. Some develop CCF in early infancy and many are asymptomatic until later life, presenting with the consequences of hypertension, e.g. cerebrovascular haemorrhage. In infants, other defects (VSD, PDA, aortic and mitral valve abnormalities) are common. Blood flow to the fetal ascending aorta and aortic isthmus is reduced, and the RV has to cope with more volume load than usual, supplying blood to the descending aorta through a PDA. The result is RV dilatation and hypertrophy, with relative hypoplasia of the LV. When the ductus closes soon after birth, the work imposed on the relatively small LV increases dramatically. Pulmonary venous congestion results in dyspnoea, and circulatory shock with renal failure quickly develops (Fig. 5).

Aortic and pulmonary valve stenosis

Both lesions produce an ejection-type of systolic murmur best heard over the area distal to the obstruction. The murmur of pulmonary valve stenosis (PS) is the loudest over the pulmonary artery (upper left sternal border) and S2 might be normal in cases of mild obstruction. In the presence of significant poststenotic dilatation with increased pulmonary artery capacity, less recoil exists to

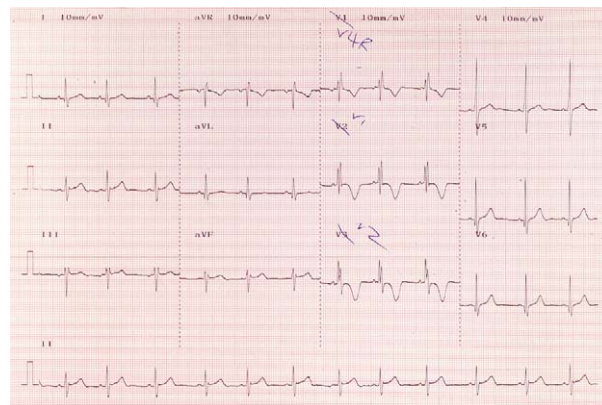


Figure 4 RsR in V1 with a superior axis, typical of a partial atrioventricular septal defect (AVSD).

promote valve closure and S2 is widely split. A2/P2 are quiet in severe AS/PS. More severe PS produces a long murmur and wide splitting of S2. A click might be generated either by sudden distension of the pulmonary artery or by abnormal valve movement. The same principles apply to cases of aortic stenosis (AS); in severe AS, S2 can be single or paradoxically split because of a delay in closure of the valve. In both lesions, severe obstruction results in ventricular hypertrophy (RVH in PS, LVH in AS). Extreme degrees of arterial valve stenosis or atresia present in the newborn period with collapse (AS) or dramatic cyanosis (PS) when the DA closes.

Mitral valve stenosis

An uncommon lesion rarely found in isolation, mitral valve stenosis (MS) increases left atrial pressure, with dilatation of the left atrium and high pulmonary venous and capillary pressure. Pulmonary oedema results, clinically manifest as dyspnoea and orthopnoea, and a diastolic murmur preceded by an opening snap is typical. S1 is loud because the mitral valve leaflets are relatively wide apart at the time of ventricular contraction. The ECG is noteworthy for RVH, and CXR for the LA enlargement, pulmonary venous congestion, RVH and a prominent PA segment.

Regurgitant lesions

The two most important valvular regurgitant lesions are MR and AR. With severe regurgitation the chambers both proximal and distal to a regurgitant valve become dilated and volume overloaded.

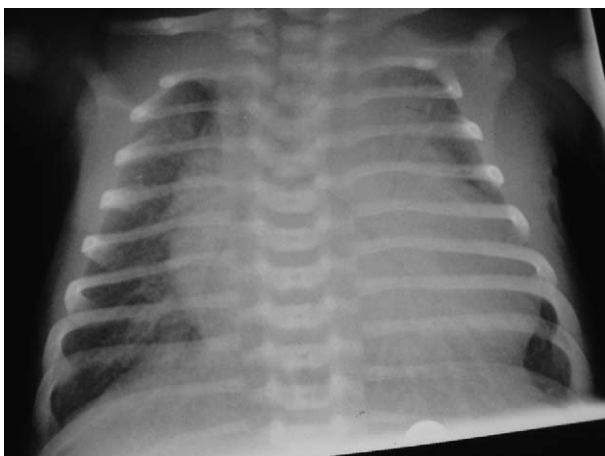


Figure 5 Typical chest X-ray (CXR) findings in neonatal aortic coarctation—pulmonary venous congestion and cardiomegaly (biventricular hypertrophy).

Aortic regurgitation

The LV is volume-overloaded as a result of handling normal cardiac output as well as the blood that leaks back into it. Stroke volume increases with the consequence that the aorta pulsates more than normal and becomes dilated.

Aortic regurgitation (AR) causes a proportional reduction in diastolic pressure, a widened pulse pressure and a bounding peripheral pulse. Shortening of diastole with exertion reduces regurgitation, meaning affected children are relatively tolerant of exercise. An early decrescendo diastolic murmur is best heard in the third intercostal space and at the apex, reflecting the direction of flow of the regurgitant jet, which itself coincides with forward flow of left atrial blood. This can produce flutter motion of the mitral valve and the so-called 'Austin-Flint' murmur in diastole.

Mitral regurgitation

Significant mitral regurgitation (MR) causes left heart volume-loading and enlargement of both LA and LV. The regurgitant flow produces a systolic murmur, and S3 is loud as a consequence of increased LV inflow. In severe cases excessive blood flow through the mitral valve produces a mid-diastolic 'rumble'.

Cyanotic congenital heart disease

Comprehensive discussion of the pathophysiology of every cyanotic lesion is beyond the capacity of this article, and so after consideration of some general principles, three of the most common cyanotic lesions will be discussed in more detail: transposition of the great arteries (TGA), tetralogy of Fallot (TOF) and total anomalous pulmonary venous drainage (TAPVD).

Pathophysiology of cyanosis

Clinically apparent cyanosis occurs when there is greater than 5 g of reduced haemoglobin per 100 ml of blood. It develops either by desaturation of arterial blood (central cyanosis) or by increased extraction of oxygen by peripheral tissues (peripheral cyanosis), as occurs in hypovolaemic shock. The blood haemoglobin (Hb) level is an important determinant of the occurrence of cyanosis and in children with a higher Hb it is more readily recognised for a given oxygen saturation.

Complete transposition of the great arteries

The aorta arises from the RV, anterior and to right of the PA, which arises from the LV. Desaturated blood returns from the body and flows out of the aorta to vital organs, again without being oxygenated in the lungs. Well-oxygenated blood returning from the lungs to the LA flows into the PA and eventually returns again to the LA. These two circuits are said to be 'in parallel' rather than 'in series', as in normal circulation. Without a communication at ductal, atrial or ventricular level, this lesion is incompatible with life. The clinical presentation of TGA varies according to the presence and size of communication at these three sites.

In the most common form of TGA, a patent foramen ovale and the ductus are the sources of communication between the two parallel circuits. Marked cyanosis is apparent from birth and the arterial oxygen saturation is typically 30–50%. Without treatment, anaerobic glycolysis results in a metabolic acidosis and reduced myocardial function. Intravenous prostaglandin E2 maintains ductal patency and shunting from the aorta (arising from the RV) to pulmonary artery (arising from the LV), thereby increasing pulmonary venous flow and LA pressure. This facilitates left-to-right shunting at atrial level and provides a link between the two parallel circuits. Balloon atrial septostomy (which increases the size of the foramen ovale) is done soon after birth and usually improves the arterial oxygen saturation by increasing interatrial shunting. As pulmonary vascular resistance falls over the first week of life, the increase in pulmonary blood flow results in LV overload and congestive cardiac failure (Fig. 6).

The presence of a VSD or large ASD with TGA produces good mixing, and in some cases an arterial oxygen saturation as high as 90% without acidosis. However, once PVR drops and pulmonary blood flow increases, the left heart becomes volume-loaded and CCF develops. S2 is single, attributed to the aorta being anterior and pulmonary valve closure being early as a result of pulmonary hypertension. The ECG shows biventricular hypertrophy, reflecting volume-overloading of the LV and the work of the RV as the systemic ventricle.

In the early newborn period a murmur is frequently absent, but in the presence of a VSD might become audible as PVR falls.

Tetralogy of Fallot

This abnormality comprises right ventricular outflow tract obstruction (RVOTO), which is always in

the subvalvar region and frequently elsewhere in the RVOT, VSD, RVH and an overriding aorta. The severity of the RVOTO is progressive with time and determines the direction and size of the shunt through the VSD. Most children are not cyanosed at birth but become so by 1 year of age. Mild RVOTO allows a left-to-right shunt and an absence of cyanosis, whereas more severe stenosis produces right-to-left shunting with cyanosis. Regardless of shunt direction, the systolic pressure is equal in the RV, LV and aorta.

In acyanotic TOF the degree of RVOTO is small, although of sufficient size to produce a pressure gradient between RV and PA. The presence of a small left-to-right shunt results in increased pulmonary blood flow and the clinical features are often mistaken for a small VSD. However, an important diagnostic clue suggestive of TOF is the presence of RVH on ECG, in contrast to a normal ECG or voltage criteria of LVH typical of an isolated small VSD. A right aortic arch on CXR further strongly supports the diagnosis.

In cyanotic TOF with moderate RVOTO and a right-to-left shunt at ventricular level, pulmonary blood flow is reduced and the pulmonary arteries are small. The ejection systolic murmur of infundibular stenosis is best heard at the left mid-sternal border, and that of valvar stenosis at the upper left sternal edge. The length and intensity of the murmur are inversely related to the degree of stenosis; mild obstruction allows more blood flow into the PA, generating a loud, long murmur; more severe obstruction restricts RV outflow and generates only a short, quiet systolic murmur. Severe RVOTO results in a low PA pressure and therefore

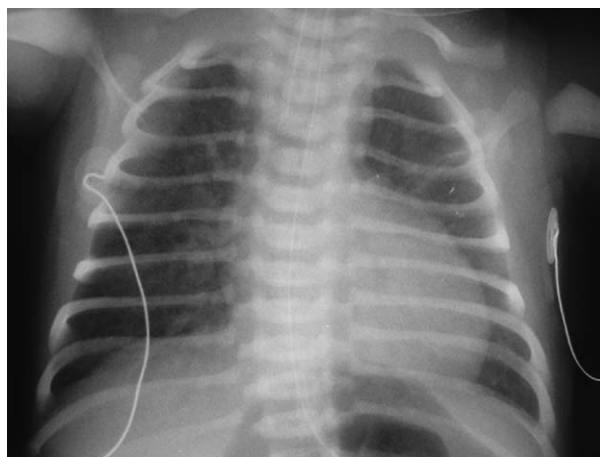


Figure 6 Typical X-ray appearances of transposition of the great arteries (TGA)—cardiomegaly, pulmonary plethora, an egg-shaped heart and a narrow mediastinum, reflecting the abnormal position of the aorta anterior to the pulmonary artery.

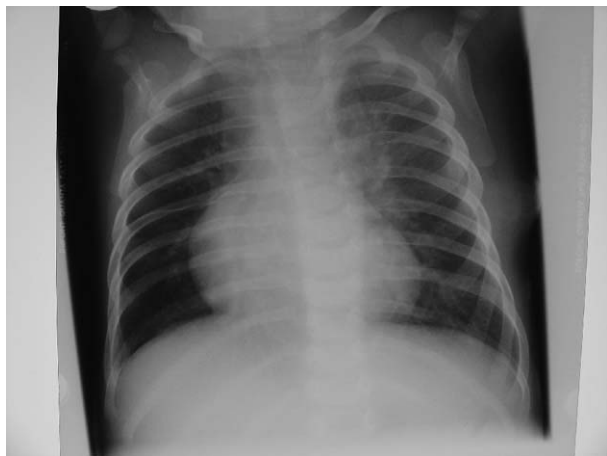

Figure 7 Right ventricular hypertrophy (RVH) and reduced pulmonary vascular markings, typical of tetralogy of Fallot.

only a soft P2. The ECG demonstrates RVH reflecting RV pressure overload (Fig. 7).

Tetralogy anatomy can be associated with pulmonary atresia, when the only source of pulmonary blood flow is through a PDA. Closure of the PDA is rapidly fatal, and so patency is maintained with a prostaglandin infusion. Marked cyanosis is a consequence of shunting of all systemic venous return right-to-left across the VSD.

Cyanotic 'spells' in TOF

The RV and LV in TOF can be thought of as a single chamber, as the VSD is of a size large enough to equalise systolic pressures. The degree of RVOTO offered by the RV infundibulum and the pulmonary valve is considered by many to be largely fixed. Flow out of the RV (pulmonary blood flow, Q_p) is determined by pulmonary vascular resistance, whereas systemic vascular resistance (SVR) determines flow out of the LV (systemic blood flow, Q_s). The balance between Q_p/Q_s is critical; a reduction in the systemic vascular resistance has the effect of preferentially favouring Q_s but reducing Q_p , whereas decreased pulmonary vascular resistance increases Q_p but can reduce Q_s .

Short-term changes in RVOTO and/or SVR affect the degree of left-to-right shunting, and a combination of these factors perhaps provides the explanation for 'spells', which can be precipitated by a number of events (e.g. defaecation, crying, exercise, hypovolaemia, tachycardia). Increased hypoxia, hypercapnoea and acidosis stimulate the respiratory centre with resultant hyperventilation. This has the effect of increasing systemic venous return, which in the presence of fixed RVOTO or decreased SVR, further increases cyanosis as the

increased venous return is pumped directly out of the RV into the aorta. This propagates the cycle further.

Treatment is aimed at breaking this cycle. Placing the infant in the knee–chest position increases the SVR by reducing femoral artery flow. It also temporarily decreases systemic venous return by restricting venous return from the legs. Administering oxygen can improve arterial oxygen saturation to a degree, but more definitive treatment using a vasoconstrictor to raise SVR (e.g. metaraminol, phenylephrine), or propranolol or morphine (which can reduce infundibular spasm) is mandatory if these simple measures do not precipitate prompt improvement. Propranolol can also be used prophylactically by virtue of its stabilising effect on arterial tone, which might prevent a sudden decrease in SVR. The natural history of spells is to become more frequent and more severe with increasing age.

Total anomalous pulmonary venous drainage

TAPVD can be subdivided anatomically into three different types: supracardiac, cardiac and infracardiac. Clinical presentation is largely dictated by whether there is obstruction to pulmonary venous return. In all types, blood can enter the left ventricle only through a PFO/ASD. Many supracardiac and cardiac types are unobstructed, whereas obstruction is common when the site of anomalous drainage is infra-cardiac.

In unobstructed TAPVD (Fig. 8), the haemodynamic consequences are similar to those found with

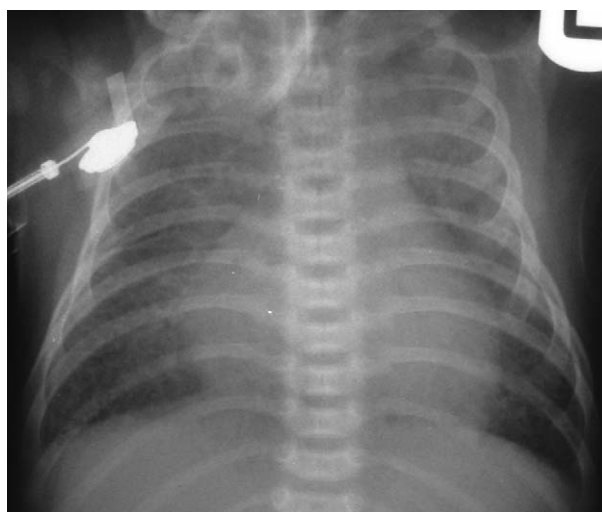


Figure 8 Unobstructed total anomalous pulmonary venous drainage (TAPVD). Right atrial (RA), right ventricular (RV) and pulmonary artery (PA) enlargement, with an increase in pulmonary vascular markings.

a large ASD. The size of the interatrial communication and the relative compliance of the ventricles influence the amount of blood that passes from RA to LA. The rapid fall in PVR that occurs shortly after birth increases RV compliance, and this, combined with an often inadequate (restrictive) interatrial communication, results in more blood entering the RV than the LA. Volume overload of the right side of the heart and pulmonary circulation results, and this is reflected clinically by the presence of a systolic murmur from pulmonary blood flow and a diastolic murmur reflecting increased tricuspid valve flow. S2 is widely split for the same reasons as it is with an ASD, and P2 might be loud because of PHT. An S3 or S4 are common. The large Qp results in only mild cyanosis, with an arterial oxygen saturation of typically 85–90%. The ECG usually shows RBBB or RVH and occasionally RAH. The CXR demonstrates RA and RV enlargement, a prominent PA segment and increased pulmonary vascular markings. The unobstructed supracardiac type is characterized in late infancy by a 'snowman' or 'cottage-loaf' radiographic appearance, a consequence of PA and left vertical vein enlargement together with pulmonary plethora.

The presentation of obstructed TAPVD is quite different and is a manifestation of pulmonary venous hypertension with secondary PA and RV hypertension. Pulmonary oedema develops once the capillary hydrostatic pressure exceeds blood osmotic pressure. Clinically, severe cyanosis with respiratory distress secondary to pulmonary oedema results. This might be apparent from birth or a few days later when pulmonary venous obstruction

increases, such as when the ductus venosus closes in the infracardiac variety. S2 is loud as a consequence of pulmonary hypertension and a heart murmur might be absent because right heart blood flow is not increased. RVH is evident on ECG, with pulmonary oedema and a relatively small heart seen on CXR. The appearance of the lung fields on X-ray can easily be mistaken for severe neonatal respiratory disease.

References

1. Park MK. Electrocardiography. In: Park MK, editor. *Pediatric cardiology for practitioners*. 4th ed. St. Louis: Mosby; 2002. p. 34–51.
2. Bernstein D. Electrocardiography. In: Behrman RE, Kliegman RM, Jenson HB, editors. *Nelson textbook of paediatrics*. 16th ed. Philadelphia: WB Saunders Company; 2000. p. 1351–5.
3. Langman J. The fetal circulation. In: Langman J, editor. *Medical embryology*. 4th ed. Baltimore/London: Williams and Wilkins; 1981. p. 197–201.
4. Arlettaz R, Archer N, Wilkinson AR. Natural history of innocent heart murmurs in newborn babies: controlled echocardiographic study. *Arch Dis Child Fetal Neonatal Ed* 1998;**78**(3):F166–70.
5. Evans NJ, Archer LN. Postnatal circulatory adaptation in healthy term and preterm neonates. *Arch Dis Child* 1990;**65**:24–6.

Further reading

1. Park MK. *Pediatric cardiology for practitioners*, 4th ed. St. Louis: Mosby; 2002.

Available online at www.sciencedirect.com

